

# Management of Torsiversion of a Tooth Secondary to a Mesiodens

## Correspondence

Pawandeep Kaur Sandhu

Virk

35-B, Udham Singh Nagar  
Civil Lines, Ludhiana- 141001  
Punjab

## ABSTRACT

A mesiodens frequently delays and interferes in the eruption of maxillary central incisors. In the present case, an unerupted mesiodens caused rotation of the permanent left maxillary central incisor. Early detection of mesiodens can prevent occlusal, a esthetic, and psychological problems in young children. Moreover, an early treatment provides for better retention. An early surgical intervention was done to extract the mesiodens and the affected tooth derotated using a semi-fixed appliance. Extraction of mesiodens in early mixed dentition period followed by timely correction of the affected permanent tooth is recommended, thereby lessening the chances of a more complex surgical and orthodontic treatment in future.

**Keywords:** Supernumerary tooth, mesiodens, derotation

Pawandeep Kaur Sandhu

Virk

Associate Professor  
Pedodontics Bhojia  
Dental College & Hospital  
Chandigarh- Nalagarh Road  
Budh (Baddi), Teh. Nalagarh  
Solon - 173 205  
Himachal Pradesh

## INTRODUCTION

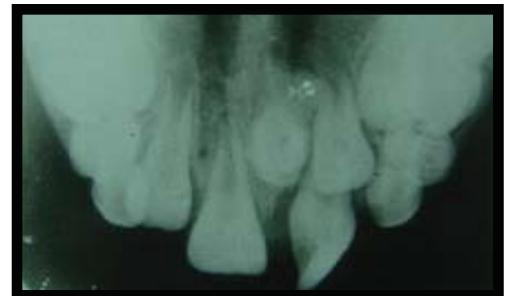Mesiodens or mesiodentes (multiple mesiodens) is the most common type of accessory supernumerary tooth present in the midline of maxilla between the two incisors [1]. It is suspected when a normal tooth is either significantly delayed in its eruption or is displaced. It has been reported that 75% of mesiodentes remain unerupted [1,2,3]. Rotation of central incisor is usually caused by the presence of mesiodens and the degree of rotation depends upon the position, depth, and angulation of the unerupted mesiodens [4]. An early diagnosis aids in early intervention and also provides for a more favorable prognosis with minimal complications.

teeth (Figure 1). The medical and dental history was non contributory. Intraoral examination revealed mixed dentition with torsiversion of the tooth 21 (FDI notation). Also, the tooth 22 had failed to erupt whereas the contralateral teeth 11 and 12 had already erupted.

Urvashi Sharma

Senior Lecturer, Pedodontics  
Dr. HSJ Institute of Dental  
Sciences & Hospital Panjab  
University Chandigarh  
(India)

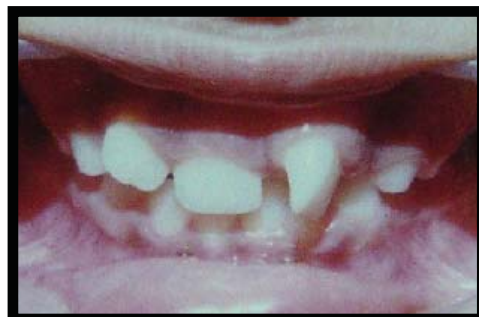Figure 2. Occlusal view of premaxilla showing the unerupted mesiodens; rotated 21 and unerupted 22



## CASE REPORT

An eight-year old reported to the Department of Pedodontics and Preventive Dentistry with a chief complaint of irregular upper front

Fig. 1. Intraoral view showing rotation of 21 and unerupted 22



An intraoral periapical radiograph and a maxillary occlusal radiograph revealed an unerupted mesiodens (Figure 2), which was surgically extracted. Thereafter, a Hawley's appliance with a modified labial bow and a palatal hook was designed to derotate the tooth 21 [Figures 3 and

Fig. 3. Hawley's appliance with the embedded palatal hook

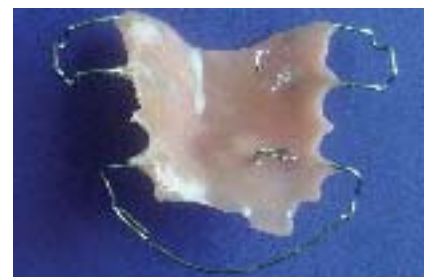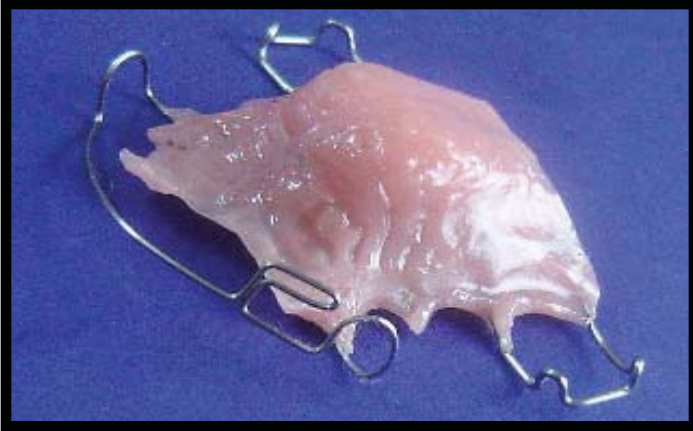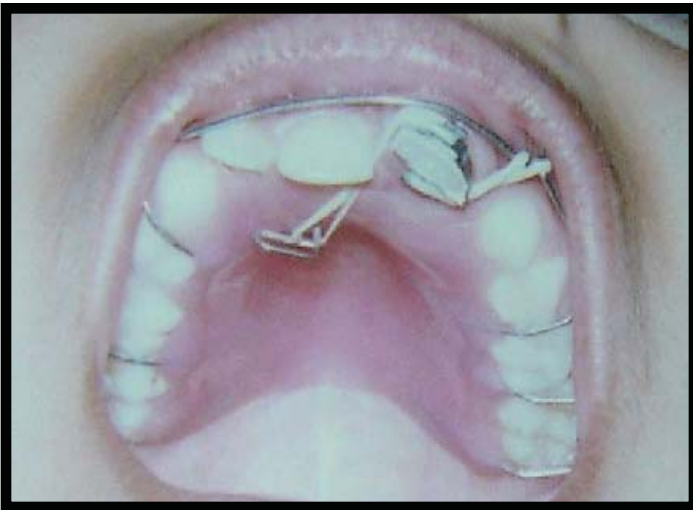


Figure 4. Hawley's appliance showing the modified labial bow



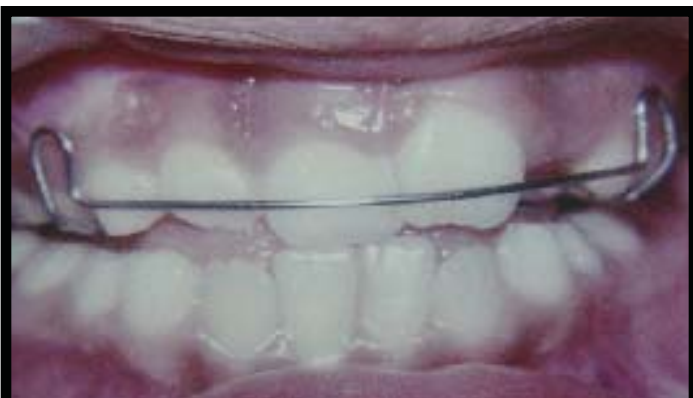4]. The affected tooth was banded and two Begg's brackets were attached to the band, one on the labial and another on the palatal side. The brackets were positioned horizontally to prevent dislodgement of elastics. 3/16" elastics were used to create a couple

Figure 5. Appliance in position



of force to derotate 21 [Figure 5]. The patient was instructed to change the elastics after every 48 hours and was reviewed periodically. After the correction of rotation, a retainer was placed [Figure 6].

Figure 6. Removable retainer after correction of rotated 21



## DISCUSSION

### Prevalence and incidence

The reported prevalence of supernumerary teeth is 0.15% to 3.9% with a higher prevalence in the Asians. Amongst the supernumerary teeth, mesiodens is the most common, with a prevalence of 0.15%-1.9% [1,3]. The male to female ratio is 2:1. Such teeth may occur in isolation or may be associated with syndromes such as Cleidocranial dysostosis, Gardner's syndrome or cleft lip/palate [3,5,6].

### Classification

Supernumerary teeth may be classified

#### 1) Chronologically:

- a. Predeciduous
- b. Bearing similarity to permanent teeth
- c. Postpermanent
- d. Complementary

#### 2) Morphologically:

- a. Supplemental teeth- morphologically similar to normal teeth
- b. Accessory teeth-morphologically different to teeth of normal series and may be
  - i. Conical
  - ii. Tuberculate
  - iii. Odontome

#### 2) Topographically:

- a. Mesiodens
- b. Supernumerary premolars-parapremolars
- c. Supernumerary molars i.e. paramolars and distomolars [1,6].

Supernumerary teeth may also be classified as unilateral or bilateral; single or multiple; syndromic or non-syndromic [4].

Mesiodentes have been classified on the basis of their

#### 1. Occurrence in primary or permanent dentition.

#### 2. Morphology:

- i. Conical, which are usually single, peg shaped, and often located palatally. These may either erupt into the oral cavity and, if inverted, may fail to erupt or there may be ectopic eruption into the nasal cavity. Such teeth frequently cause rotation or displacement of incisors and are rarely associated with delayed eruption.
- ii. Tuberculate teeth are barrel shaped with multiple cusps or tubercles having an abnormal or incomplete root. These teeth may be unilateral or bilateral and are associated with other supernumerary teeth. However, they develop later than conical mesiodens and are rarely associated with delayed eruption.
- iii. Molariform have a premolar-like crown with a completely formed root but these are rare [3,5].

## Etiology

The etiology of mesiodens is not well understood. The various theories proposed are hereditary, phylogenetic reversion (atavism), embryologic aberrations, progress zone theory (hyperactivity of dental lamina), and unified etiology theory [1,3,6].

## Clinical and radiograph assessment

The detection of mesiodens is either an incidental finding or follows investigation of an occlusal anomaly, confirmed by radiography.

## Clinical features

The main complications are delay in or prevention of eruption (26%-52%); ectopic eruption; displacement or rotation of permanent teeth (28%-63%); labial displacement of incisors (82%). Others include crowding; diastema; dilacerations; root resorption; loss of vitality of incisors; cyst formation; and, rarely, ectopic eruption into the nasal cavity or antrum (4%-9%) [3].

## Radiographic assessment

It involves obtaining two intraoral periapical and a maxillary occlusal film analyzed according to parallax rule [1,3]. A lateral skull radiograph aids in determining the depth and height of supernumerary teeth whereas a panoramic radiograph has limited value due to lack of clarity in the midline but can provide additional information of any associated pathology [1,3,4].

**Management:** It involves either

1. Maintenance in situ with an appropriate follow up or;
2. Surgical removal, early or delayed

Extraction is not always the treatment of choice [5]. Mesiodentes are maintained in-situ when satisfactory eruption of related teeth has taken place and there is no associated pathology. Another indication is when extraction of mesiodentes is likely to compromise the vitality of related teeth [1]. Removal of mesiodens is indicated when there is a delay in eruption or prevention of eruption of central incisor(s); displacement or rotation of central incisor(s) an associated pathology; spontaneous eruption of supernumerary teeth; their presence may comprise secondary bone grafting in cleft lip and palate patient [1,5].

An early surgical intervention is planned as soon as a mesiodens is diagnosed. The drawback of this approach is that apart from compromising the vitality of the associated permanent tooth, it can adversely affect child psychology with the development of fear

towards dentistry. In some cases, surgery is better delayed till the root formation of adjacent permanent teeth is complete. However, this method is associated with loss of eruptive forces of adjacent teeth; cyst formation; space loss; crowding of arch and midline shift [3,7].

Corrections of rotation have been attempted at various stages of root development and an early correction of rotated teeth before root completion is conducive to better retention [8]. An early surgical removal of mesiodens is indicated to prevent relapse which is common in rotated teeth and a longer retention period advised [7]. Post treatment, a standard Hawley, a vacuum-formed retainer or a bonded lingual retainer is recommended [3].

## REFERENCES

1. DePasquale S, Azzopardi A, Camilleri S. Mesiodens preventing the eruption of permanent central incisor. *Malta Med J* 2005; 17: 37-39.
2. Nikhil S, Vineeta, Gupta P. Inverted mesiodens –a case report. *J Indian Soc Pedod Prev Dent* 1999; 17: 111-112.
3. Russell KA, Folwarczna MA. Mesiodens-diagnosis and management of a common supernumerary tooth. *J Can Dent Assoc* 2003; 69: 362-366.
4. Nashashibi IA. Management and effect of mesiodens teeth on the upper central incisor. *Saudi Dent J* 1989; 1: 18-22.
5. Garvey MT, Barry HJ, Blake M. Supernumerary teeth—an overview of classification, diagnosis and management. *J Can Dent Assoc* 1999; 65: 612-616.
6. Scanlan PJ, Hodges SJ. Supernumerary premolar teeth in siblings. *Br J Orthod* 1997; 24: 297-300.
7. Roychoudhury A, Gupta Y, Parkash H. Mesiodens: a retrospective study of fifty teeth. *J Indian Soc Pedod Prev Dent* 2000; 18: 144-146.
8. Prasad VN, Utreja A, Goyal A, Chawla HS. Winged maxillary central incisors with unusual morphology: a unique presentation and early treatment. *Angle Orthod* 2005; 75: 478-482.